

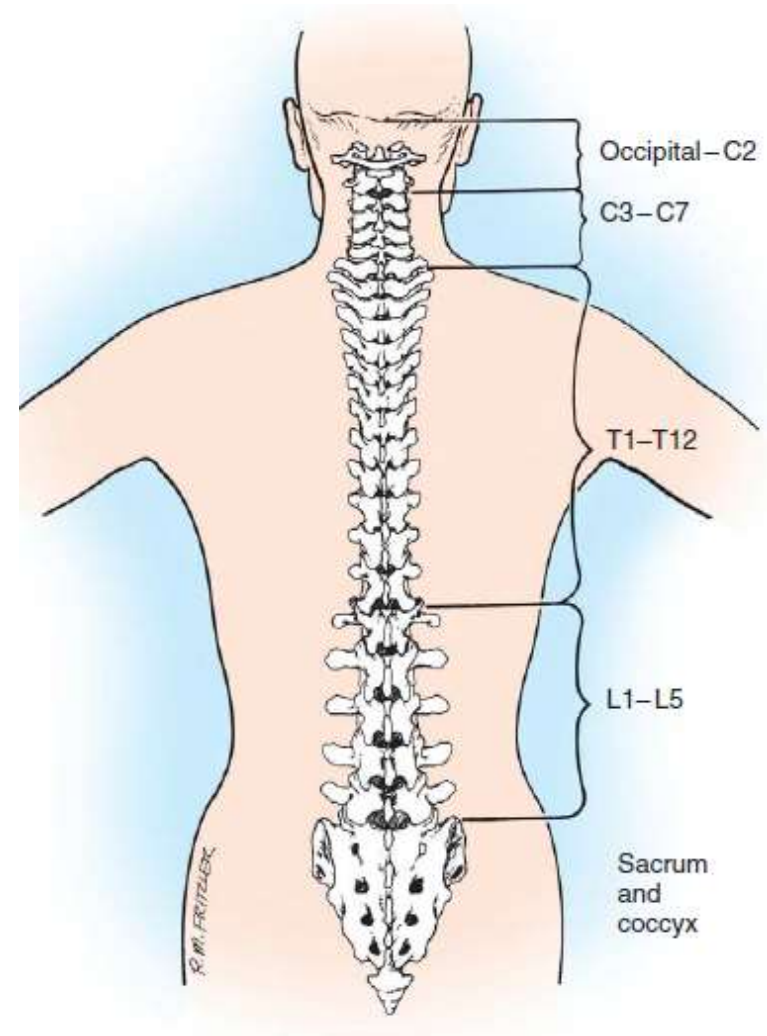
# **Spinal Fractures**

**Dr. Ahmed Saleh**

# Anatomy: **“A surgeon without anatomy like a sailor without a map”**

---

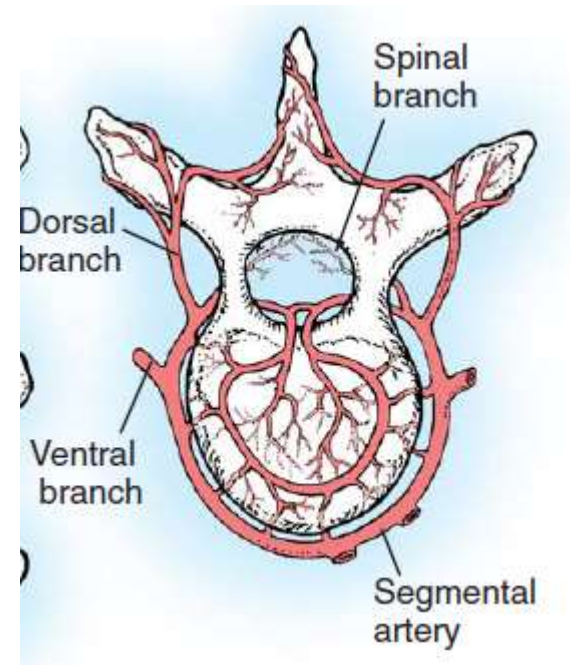
- ▶ Vertebral column
- ▶ Spinal cord
- ▶ Blood supply



# Arterial blood supply ( Segmental arteries)

---

- ▶ The thoracic and lumbar segmental arteries arise from the aorta;
- ▶ The cervical segmental arteries arise from the vertebral arteries, the costocervical, thyrocervical and the ascending pharyngeal arteries.



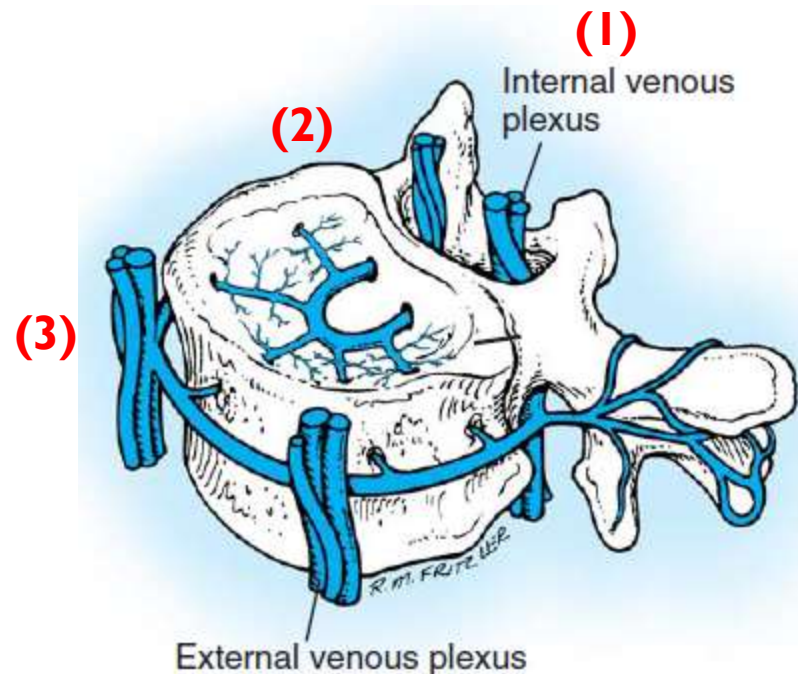
# Venous drainage ( Batson plexus)

## ▶ Components:

1. Extradural venous plexus
2. Veins of the bony structures of the spinal column.
3. Extravertebral venous plexus

## ▶ Significance:

- ▶ Communicates directly with the venous system draining the head, chest, and abdomen (through the superior and inferior vena cava and the azygos system).
- ▶ This interconnection allows spread of neoplastic or infectious disease from the pelvis to the vertebral column.



# Surgical Exposure

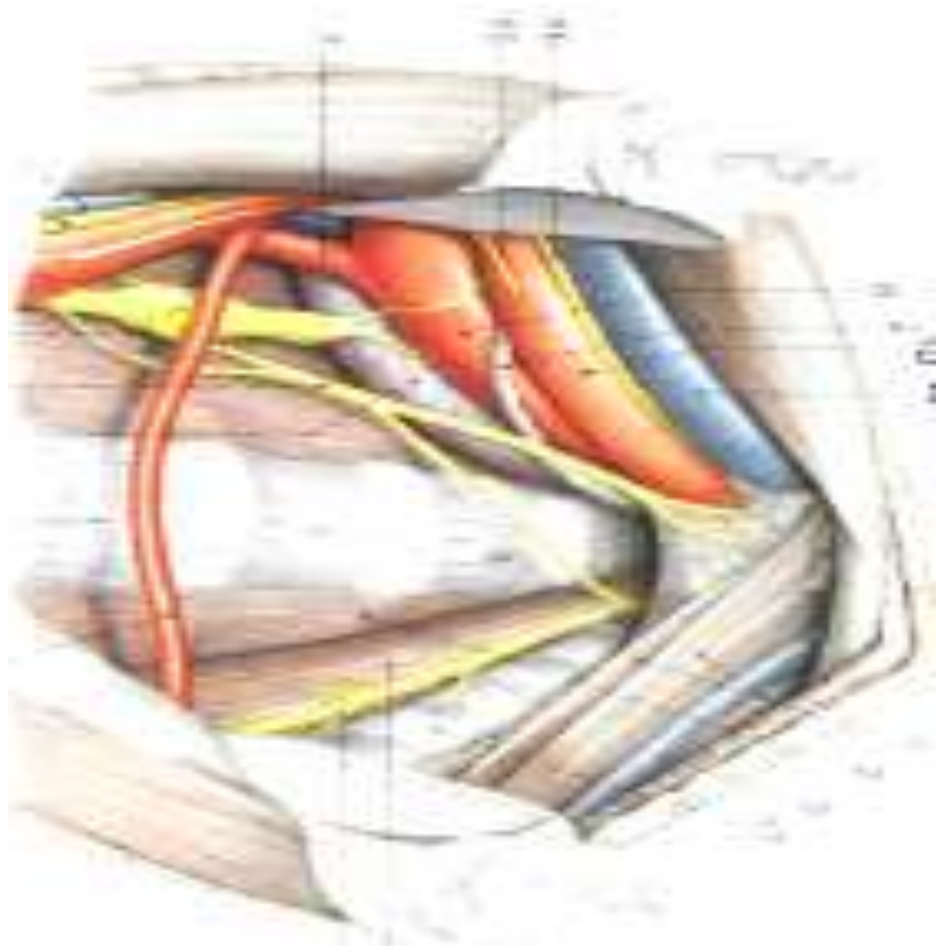
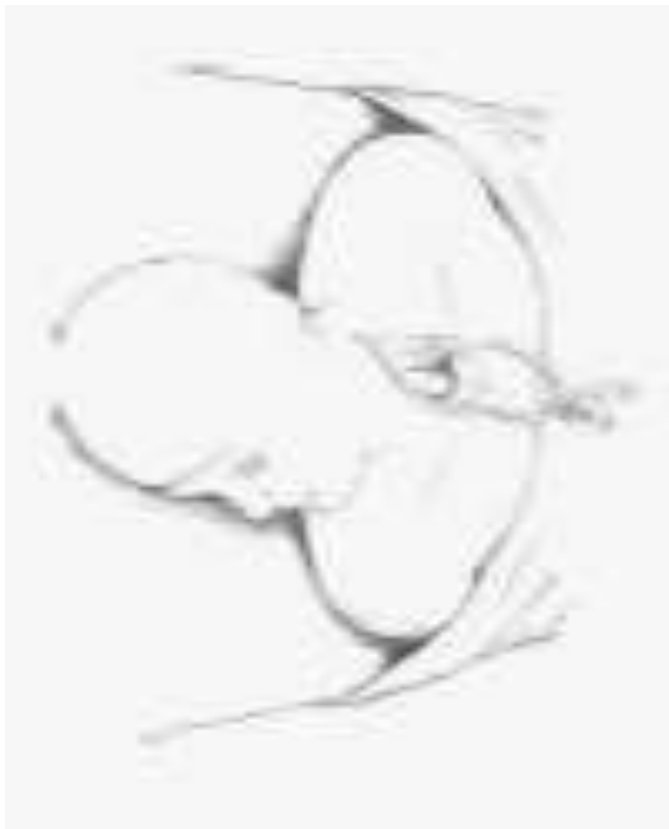---

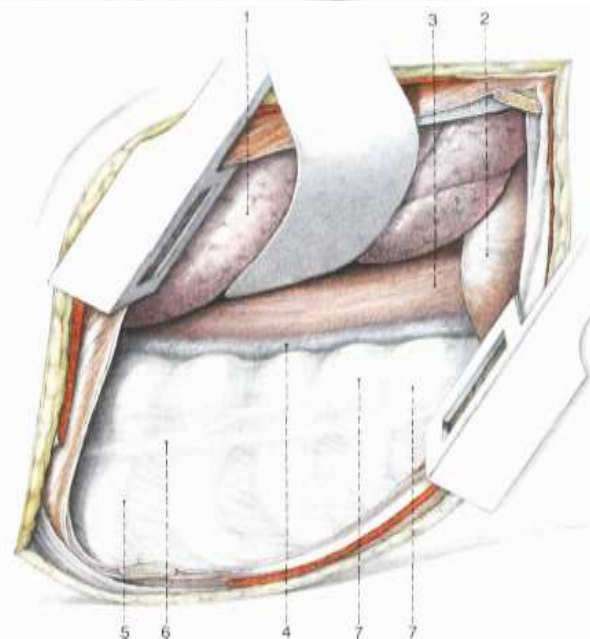
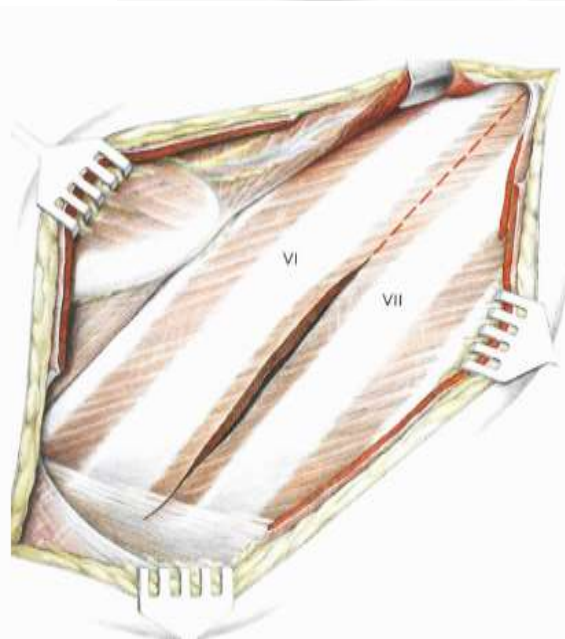
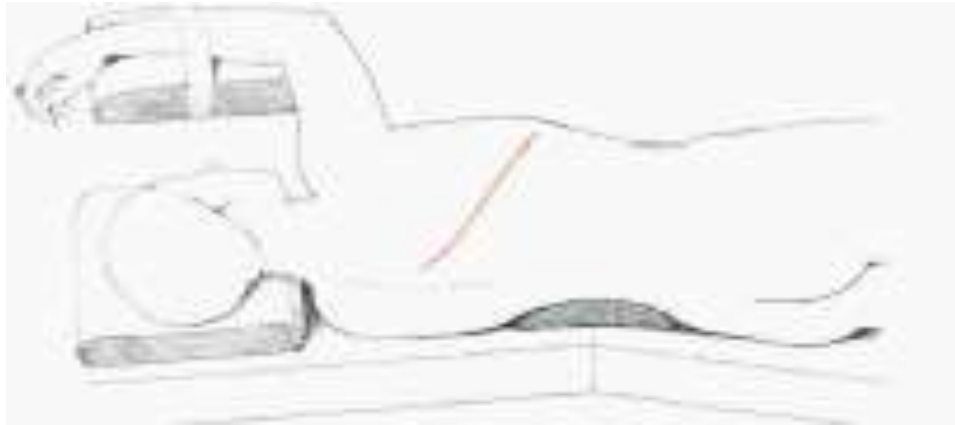
- ▶ Anterior
- ▶ Posterior
- ▶ Both (360° fusion)

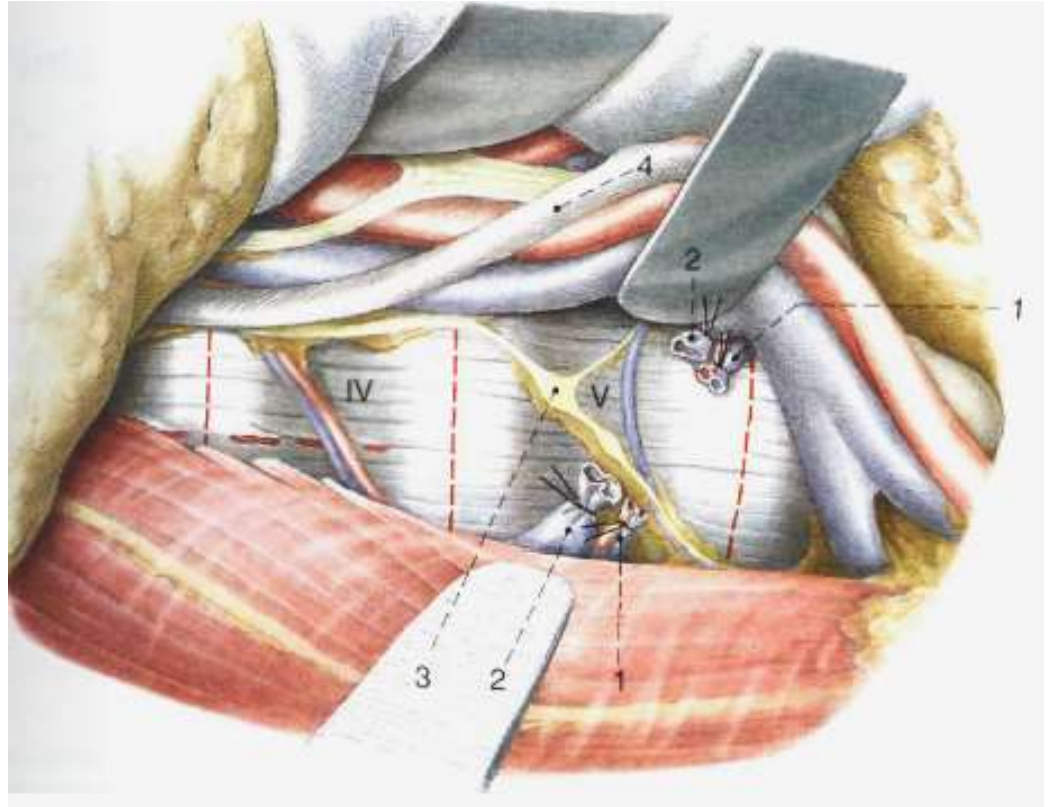
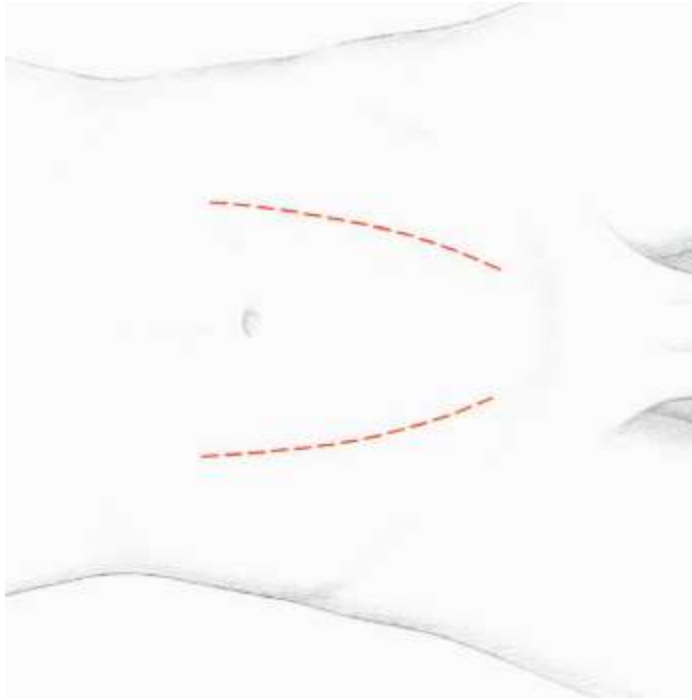


# Anterior Approaches

---



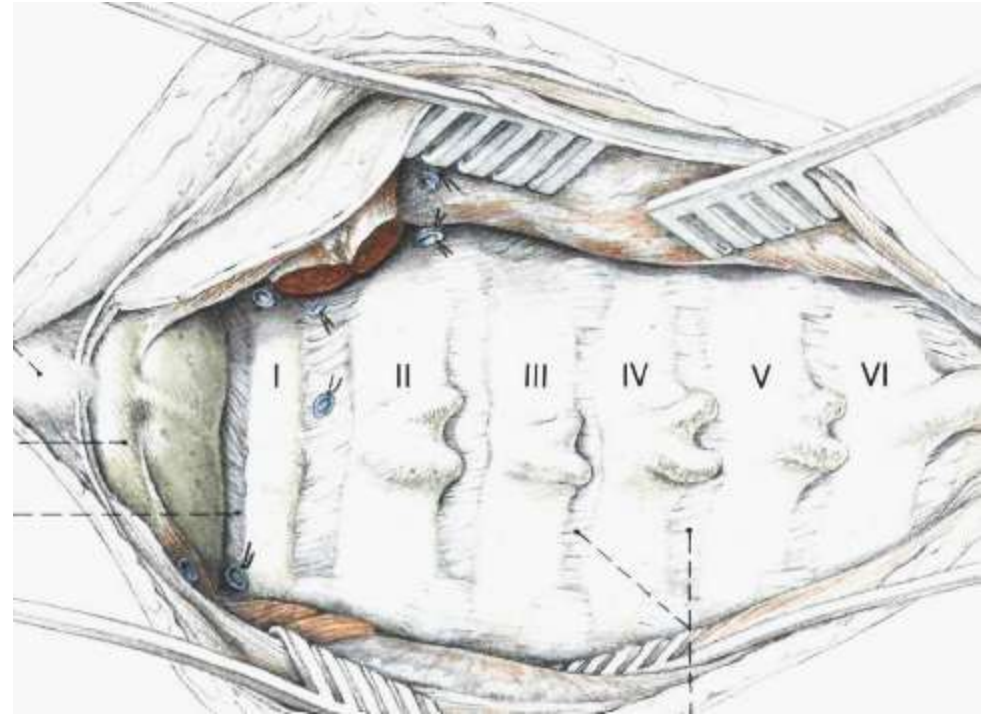
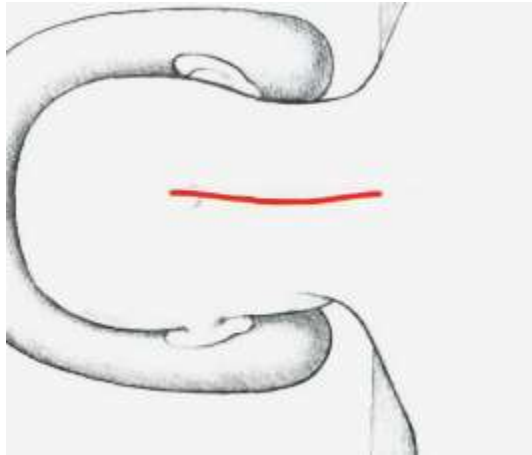


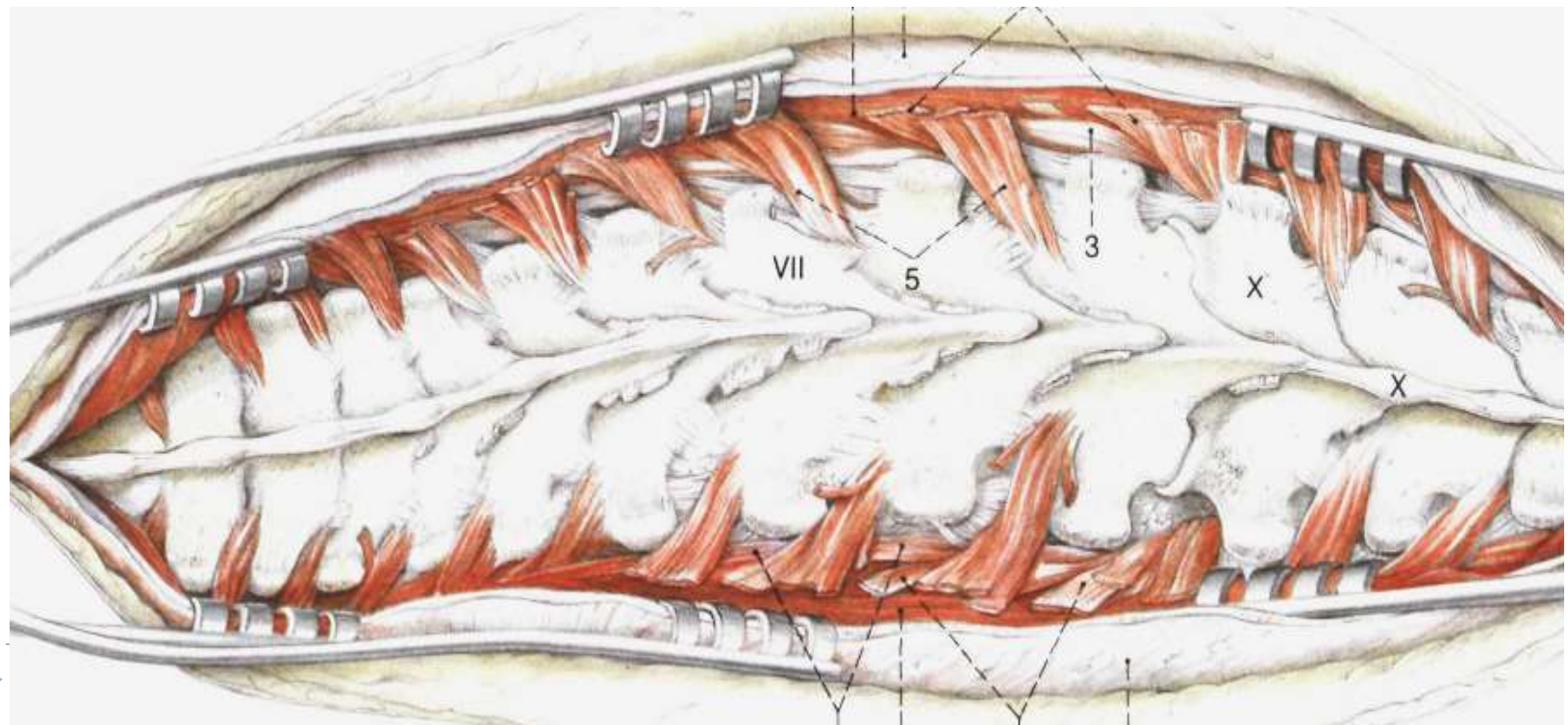
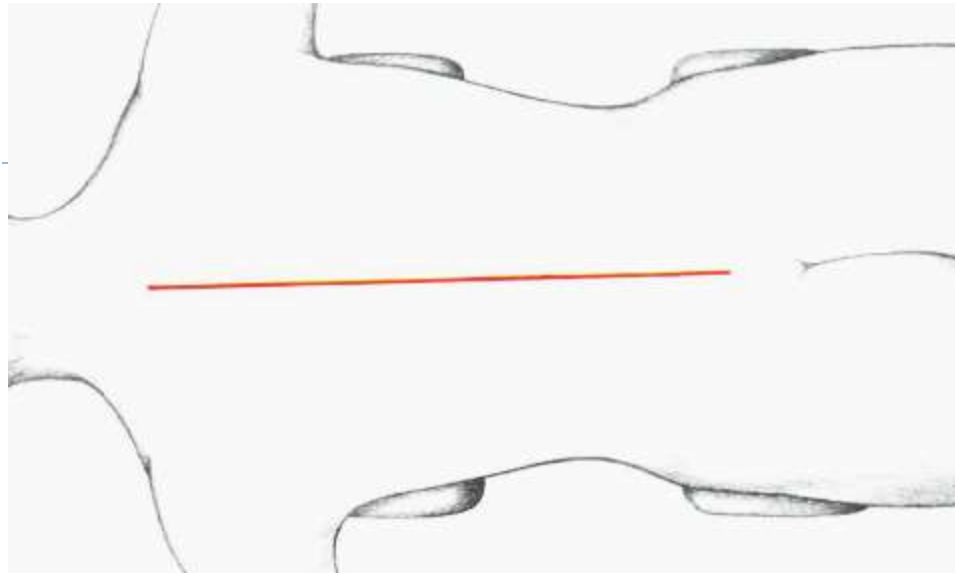




# Posterior Approaches

---





---

▶ **Aetiology:**

- ▶ MCA, FFH, fire arm injury.

▶ **History**

- ▶ Spinal injury should be suspected in any patient with a head injury or severe facial or scalp lacerations.
- ▶ In any patient with recent trauma, complaints of neck pain or spinal pain should be considered indicative of a spinal injury until proved otherwise.



# Examination

---

- ▶ **The spine should be protected during examination.**
- ▶ Inspection:
  - ▶ Ecchymosis and abrasions
- ▶ Palpation:
  - ▶ The spinous processes should be palpated from the upper cervical to the lumbosacral region. A painful spinous process may indicate a spinal injury.
  - ▶ Palpable defects in the interspinous ligaments may indicate disruption of the supporting ligamentous complex.
- ▶ Neurological examination:
  - ▶ Level of consciousness (Glasgow Coma Scale)
  - ▶ Motor, sensory and reflex examination



---

▶ **Incomplete spinal cord injury:**

- ▶ Some motor or sensory function distal to the cord injury.

▶ **Complete spinal cord injury:**

- ▶ Total motor and sensory loss distal to the injury.

▶ **Spinal shock:**

- ▶ Total motor and sensory loss distal to the injury.
- ▶ Blood pressure decreased without a compensatory increase in pulse.
- ▶ Generally resolves within 24 hours, it may last longer.
- ▶ DD: Complete spinal cord injury X Spinal shock
- ▶ A positive bulbocavernosus reflex or return of the anal wink reflex indicates the end of spinal shock. If no motor or sensory function below the level of injury when spinal shock ends, a complete spinal cord injury is present. and the prognosis is poor for recovery of distal motor or sensory function.



# Incomplete spinal cord injury

---

1. Central cord syndrome
2. *Brown-Séquard syndrome*
3. *Anterior cord syndrome*
4. *Posterior cord syndrome*
5. *Conus medullaris syndrome*
6. *Cauda equina syndrome*



# *Central cord syndrome*

---

- ▶ The most common.
- ▶ Due to hyperextension injury.
- ▶ Destruction of the central area of the spinal cord.
- ▶ The centrally located arm tracts in the cortical spinal area are the most severely affected, and the leg tracts are affected to a lesser extent. Generally, patients have a quadriparesis involving the upper extremities to a greater degree than the lower.



## *Brown-Séquard syndrome*

---

- ▶ Injury to either half of the spinal cord
- ▶ Due to a unilateral laminar or pedicle fracture, penetrating injury, or rotational injury resulting in a subluxation.
- ▶ Motor weakness on the side of the lesion and the contralateral loss of pain and temperature sensation.





## *Anterior cord syndrome*

---

- ▶ Due to hyperflexion injury in which bone or disc fragments compress the anterior spinal artery and cord.
- ▶ It is characterized by complete motor loss and loss of pain and temperature discrimination below the level of injury. The posterior columns are spared to varying degrees, resulting in preservation of deep touch, position sense, and vibratory sensation.



## *Posterior cord syndrome*

---

- ▶ Rare and usually is caused by an extension injury.
- ▶ involves the dorsal columns of the spinal cord and produces loss of proprioception and vibration sense, while preserving other sensory and motor functions.



## *Conus medullaris syndrome*

---

- ▶ injury of the sacral cord (conus) and lumbar nerve roots.
- ▶ Due to lesion between T11 and L1.
- ▶ loss of all bladder and perianal muscle control. Motor function in the lower extremities between L1 and L4 may be present if nerve root sparing occurs.



# *Cauda equina syndrome*

---

- ▶ Injury below L1
- ▶ Areflexic bladder, bowel, and lower limbs.
- ▶ Possibility of return of function (peripheral nervous system).



# Investigations

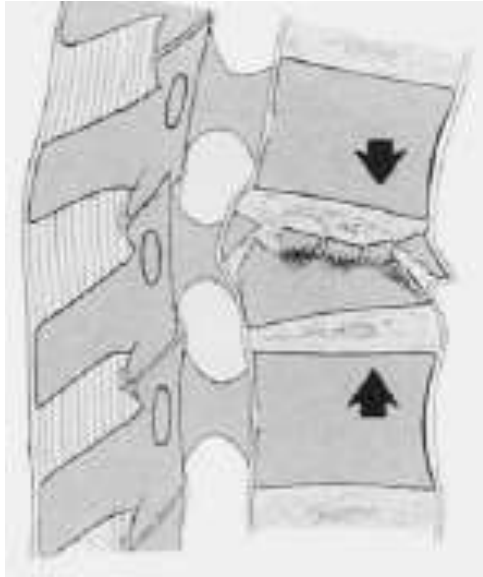
---

- ▶ **Xray**
- ▶ **CT** (occult lesions, canal compromise)
- ▶ **MRI** (ST injury, Spinal cord injuries without radiographic abnormalities (SCIWORA))

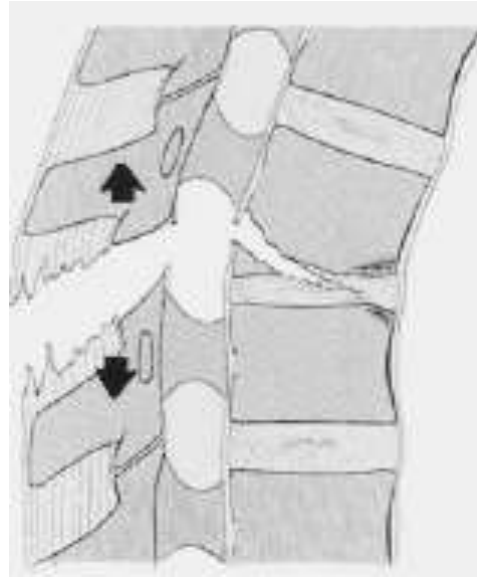


# Classification (AO)

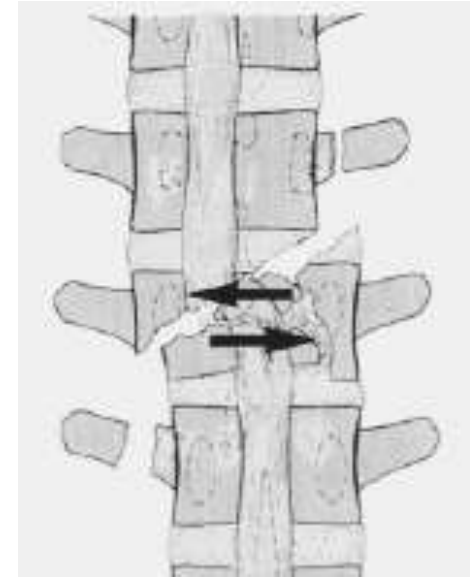
---



**Type A: Compression**



**Type B: Distraction**



**Type C: Rotation**



# Management

---

- ▶ **Emergency Treatment:**

- ▶ Immobilization ( rigid board, cervical collar)
- ▶ High-dose methylprednisolone infusion within 8 hours of injury.



---

▶ **Definitive Treatment:**

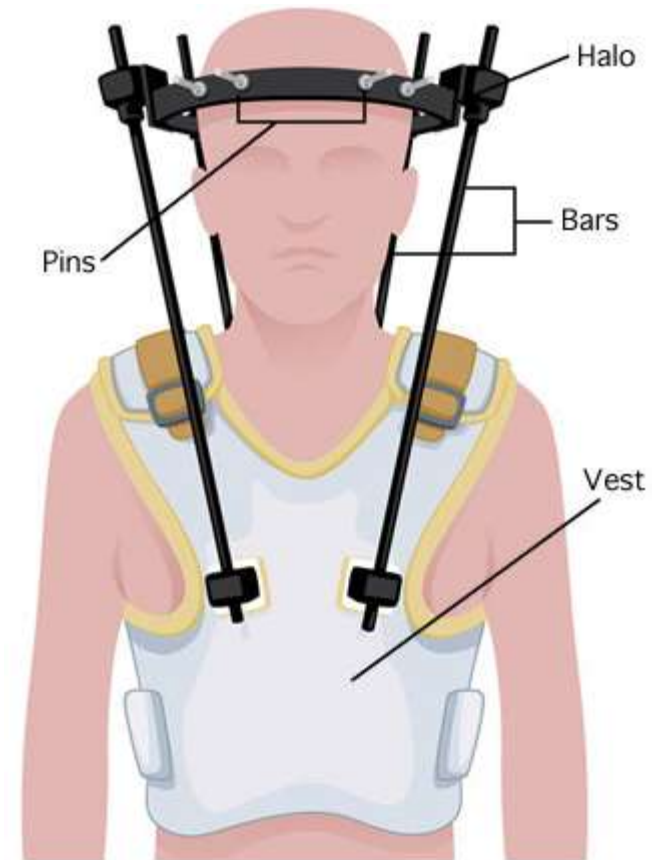
▶ **Nonoperative:**

▶ **Indications:**

- Stable compression fractures

▶ **Methods:**

- Cervical collar or halo vest.
- Lumbo-sacral or thoraco-lumbo-sacral brace.





---

▶ **Operative:**

▶ **Indications:**

- Unstable fractures with or without neurological deficit.

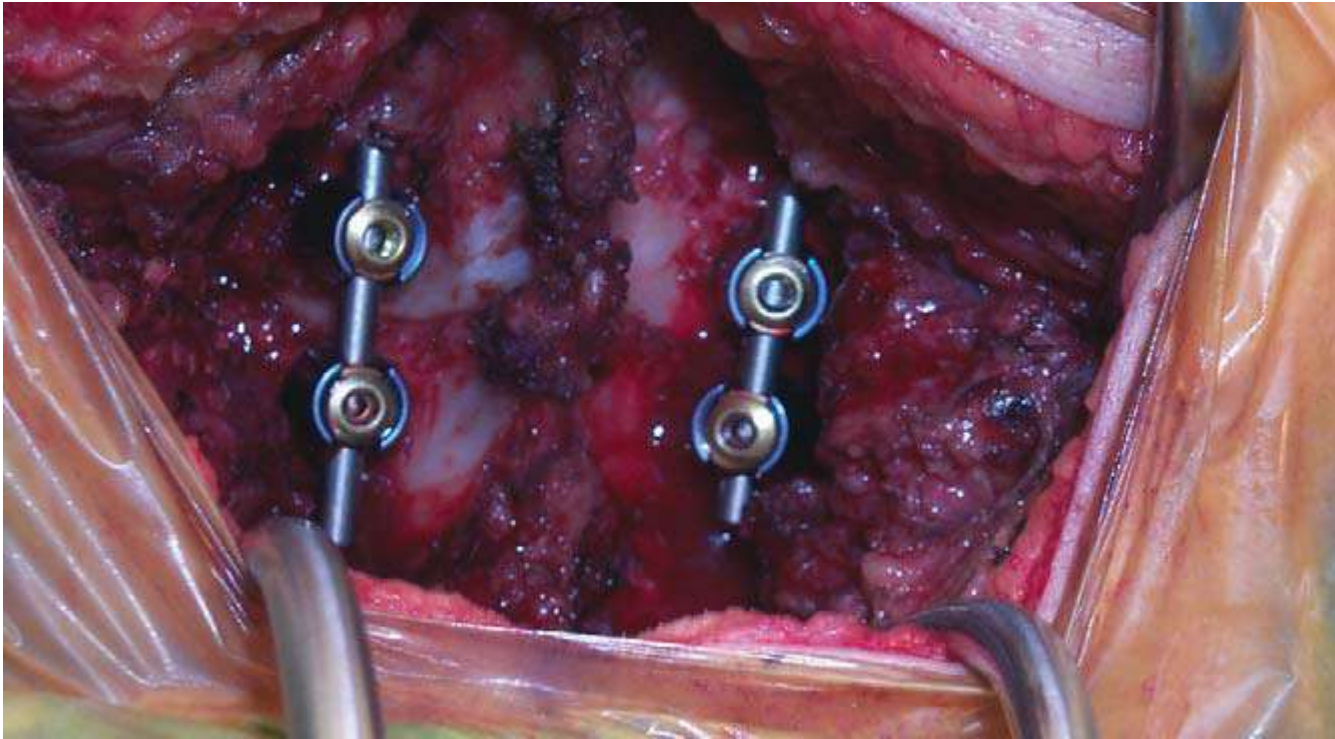
▶ **Methods:**

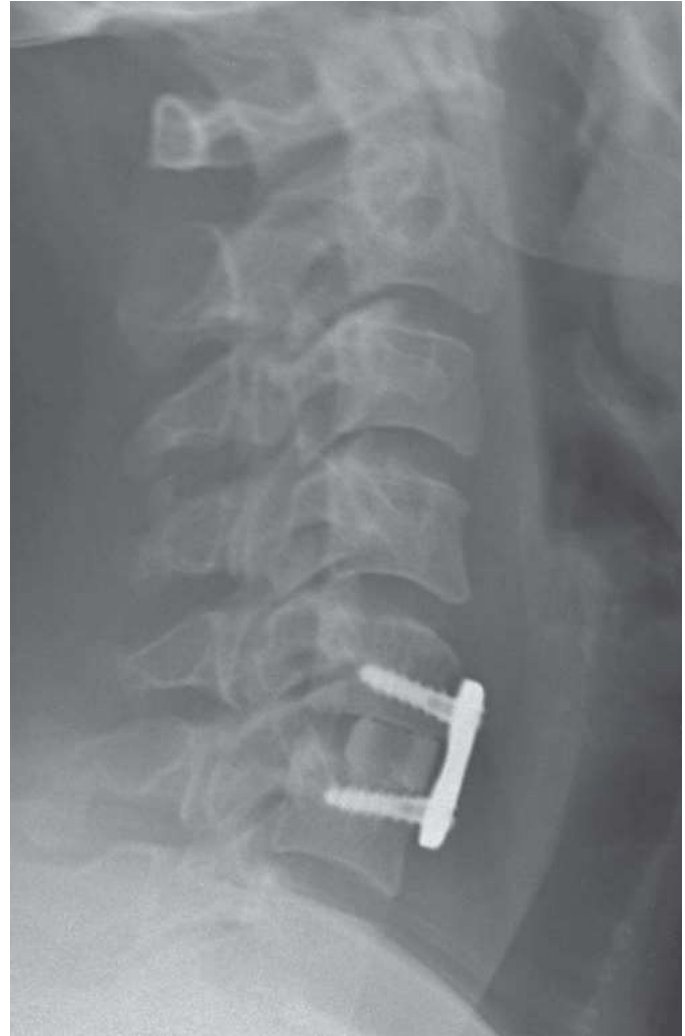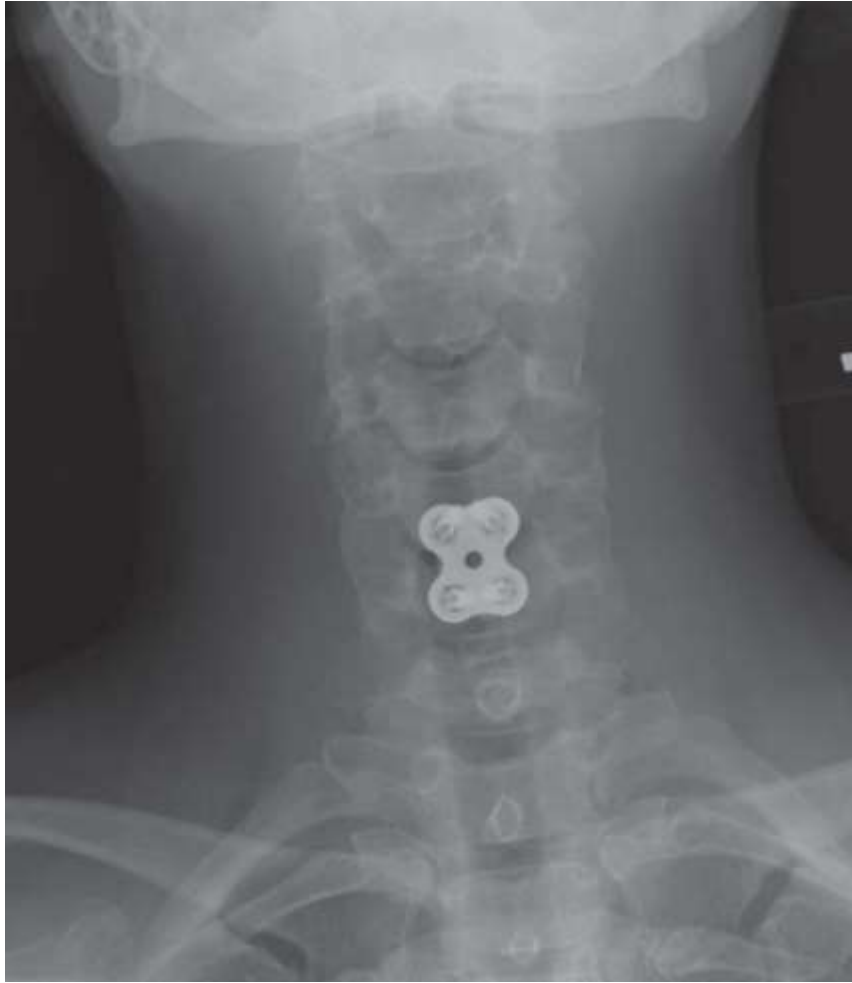- Internal fixation with or without decompression (anterior, posterior, or combined approach)



# Post

---





- 
- ▶ God willing, next lecture is:

# Spinal infections

